

## Immunopathologic study of erythema dyschromicum perstans (ashy dermatosis)

Luz A. Vásquez-Ochoa\*†, MD, Diana M. Isaza-Guzmán‡¶, MSc, Beatriz Orozco-Mora\*, MD, Rodrigo Restrepo-Molina\*, MD, Judith Trujillo-Perez\*, BLC, and Félix J. Tapia§, MPH

From the \*Universidad Pontificia Bolivariana, Medellín, †Hospital Pablo Tobón Uribe, Medellín, ‡Instituto Colombiano de Medicina Tropical, Sabaneta, ¶Universidad de Antioquia, Medellín, Colombia, and §Instituto de Biomedicina, Universidad Central de Venezuela, Caracas, Venezuela

### Correspondence

Luz Adriana Vasquez-Ochoa  
Diagonal 75 DD N°4–41  
Bloque 54,  
Apt. 401  
Medellín  
Colombia  
E-mail: gigonzal@epm.net.co

### Abstract

Erythema dyschromicum perstans (EDP) is a pigmentary disease of unknown etiology in which damage to basal cells is thought to be mediated by adhesion molecules. The aim of this study was to characterize the histopathology and immunopathology of EDP. Forty-three patients from Medellín, Colombia, with the diagnosis of EDP were evaluated. Skin biopsy specimens were obtained for histopathology and immunohistochemistry, using monoclonal antibodies directed against the following markers: CD4, CD8, CD56, CD1a, CD68, CLA, HLA-DR, ICAM-1 and LFA-1 $\alpha$ .

A dermal lymphocytic infiltrate was observed in all cases, with a perivascular location in 86%. Other histologic features included melanophages in all specimens, vacuolization of the basement membrane zone (BMZ) 58% and exocytosis of lymphocytes (53.5%). The mean number of total leukocytes was 1510 cells mm<sup>-2</sup> of tissue. There was a predominance of CD8<sup>+</sup> T lymphocytes in the dermis and HLA-DR<sup>+</sup>, ICAM-1<sup>+</sup> keratinocytes in the epidermis. Exocytosis of cutaneous lymphocyte antigen (CLA) + cells was observed in areas of BMZ damage, suggesting that response to antigenic stimulation may play a role in the development of EDP.

### Introduction

Erythema dyschromicum perstans (EDP), or ashy dermatosis, is an idiopathic dermal melanosis first described by Ramirez<sup>1-4</sup> in 1957 in El Salvador; it typically occurs in the second decade of life, more often in women, and generally affects those with type IV skin.<sup>2,5-8</sup> It has been described mainly in patients from tropical areas of Central and South America.<sup>5,9,11,12</sup> Multiple factors, such as parasites, atopy, hypothyroidism and contact with chemical substances, have been implicated in the development of EDP, but the etiology remains obscure.<sup>5,16</sup> It has been postulated that damage to melanocytes and basal layer keratinocytes<sup>1,17</sup> results from an abnormal immune response to antigens.<sup>17,18</sup> Opinions vary about whether EDP is an abortive form of lichen planus (LP) or a distinct entity.<sup>1,19-22</sup>

The characteristic clinical signs of EDP include gray macules with erythematous borders, which converge and cover variable percentages of the body surface. The most common histopathological findings are a dermal perivascular lymphocytic infiltrate with many melanophages, vacuolization of the basement membrane zone (BMZ), necrotic keratinocytes in the basal layer, colloid bodies, exocytosis of lymphocytes, and incontinence of the pigment.<sup>5,17,19,21,23-26</sup> It has been postulated that adhesion molecules such as leukocyte

function-associated antigen (LFA-1 $\beta$ ) and intercellular adhesion molecule-1 (ICAM-1), and molecules of the class II major histocompatibility complex (MHC-II/HLA-DR), may play a role in the development of abnormal melanocytes and BMZ damage.<sup>4,17,21,27-29</sup> The presence of interleukin-2 (IL-2), interferon-gamma (IFN- $\gamma$ ), natural killer (NK) cells and cytotoxic T cells in lesions of EDP is evidence that the immune system participates in this disease.<sup>5,27,30,31</sup>

There have been no published studies from Colombia concerning the immunopathology of EDP. Hence, we examined the histopathological findings along with the immunohistochemical features to help elucidate the immunopathology of EDP.

### Materials and Methods

All patients with EDP, from 1994–2000, observed at the Laboratorio Departamental de Salud Pública de Antioquia in Medellín, Colombia, were included for study. After clinical evaluation and documentation of the medical history, two 4-mm punch biopsy specimens were obtained from the border of a lesion. Histopathology examination was performed on formalin-fixed paraffin-embedded sections stained with hematoxylin and eosin, and an immunohistochemical study was conducted on tissue that was snap-frozen in liquid nitrogen.

Immunohistochemistry was performed using monoclonal antibodies that recognize Langerhans cells (CD1a), macrophages (CD68), T-helper/inducer lymphocytes (CD4), cytotoxic T lymphocytes (CD8), NK cells (CD56), adhesion molecules LFA-1 $\alpha$  (CD11a/CD18) and ICAM-1 (CD54), HLA-DR (MHC-II/HLA-DR) and cutaneous lymphocyte antigen (CLA). All antibodies were obtained from DAKO (Carpinteria, CA), except ICAM-1 and CLA (Biodesign International™, Saco, MN) and CD68 (Pharmingen, San Diego, CA). Except for localization of CD68, immunostaining was performed by the avidin-biotin-peroxidase method described by Isaza *et al.*<sup>32</sup> To evaluate CD68 expression, an indirect immunofluorescence test was used.

Cell counts were carried out using a light microscope with an ocular grid calibrated to determine the number of cells per square-millimeter (cells mm<sup>-2</sup>) in epidermal and dermal infiltrates. The area of the grid for cell counting was 0.0196 mm<sup>2</sup> using a  $\times 40$  objective.

Immunostained cells were counted in 10 fields in each of two tissue sections. In most cases, this count represented the total infiltrate because the cellular density of the dermis was low. In evaluating the epidermis, cells that had one nucleus and at least two dendrites were counted as Langerhans cells.

## Results

Of the 43 patients (56% male, 44% female) enrolled in the study, 65% were from the urban area of Medellín city. The mean age was 36 years (range 10–67 years). There was a predominance of type IV skin (49%), followed by type III (37%) and type V (14%); no patients had skin types I, II, or VI. Brown-grayish macules were observed in 24 patients (55%) and 11 patients (25%) had grayish macules and only five patients (12%) presented with macules that lacked erythematous borders. All patients had multiple lesions, and in 67% of cases three or four sites were affected, most often the anterior thorax (69%), followed by the lower limbs (67%), neck (67%), face (65%), and less frequently the posterior thorax (28%) and upper limbs (25%). On questioning, approximately half the patients noted that lesions were associated with pruritus and that there was no personal or family history of EDP.

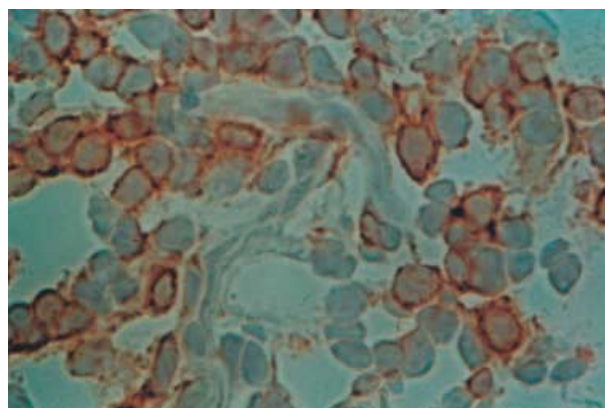
Histologic evaluation of specimens from the 43 patients showed in all cases a dermal lymphocytic infiltrate and melanophages: vacuolization of the BMZ in 58%, colloid bodies in 42% and exocytosis of lymphocytes in 54% of biopsies. No granulomas were observed. The dermal infiltrate was perivascular in 37 patients (86%), diffuse in four patients (9%), and band-like in two patients (5%). The average number of total mononuclear cells in the dermal infiltrate was 1510 cells mm<sup>-2</sup>.

Immunohistochemistry was performed on biopsy specimens from 36 of the 43 patients. The density of lymphocytes by immunophenotype and expression of adhesion molecules is displayed in Table 1. There was a slight predominance of

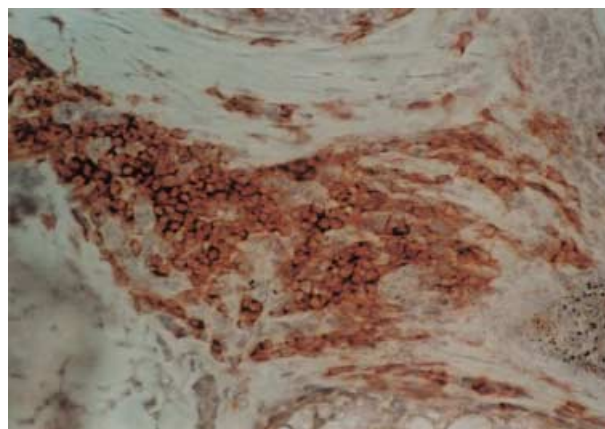
**Table 1** Density of lymphocytes by immunophenotype in lesions of erythema dyschromicum perstans

Cell surface markers in dermis	Sample (n)	Lymphocyte density (cells mm <sup>2</sup> )*	Percentage (%)
CD4	33	158.8 $\pm$ 22	10.5 $\pm$ 1.4
CD8	36	189.2 $\pm$ 29	12.5 $\pm$ 0.9
CD68	25	176.2 $\pm$ 22	11.7 $\pm$ 1.1
CD56	36	12.6 $\pm$ 1.9	0.8 $\pm$ 0.06
CLA	34	74.0 $\pm$ 8.2	4.9 $\pm$ 0.64
ICAM-1	32	76.1 $\pm$ 10	5.0 $\pm$ 0.7
LFA-1 $\alpha$	35	316.9 $\pm$ 35	21.0 $\pm$ 1.8
CD4/CD8 ratio	33	0.83	

\*Mean value of cells mm<sup>-2</sup>  $\pm$  standard error (SEM).

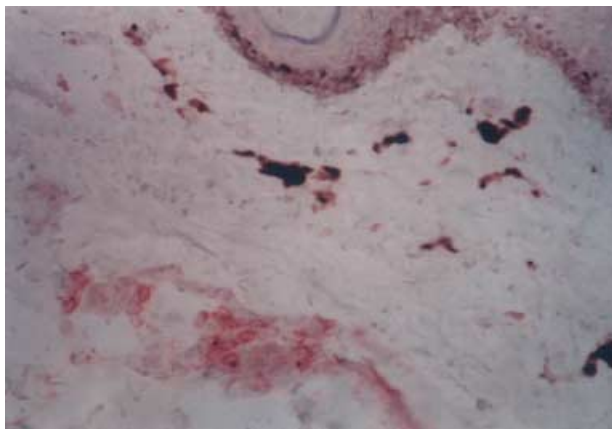


**Figure 1** CD4+ cells in dermis ( $\times 400$ )



**Figure 2** LFA-1 $\alpha$  expression by dermal lymphocytes ( $\times 100$ )

CD8<sup>+</sup> over CD4<sup>+</sup> lymphocytes (Fig. 1), with a CD4/CD8 ratio of 0.83. Expression of LFA-1 $\alpha$  was abundant in the dermal infiltrates (Table 1, Fig. 2). There were CLA-positive lymphocytes in all 34 cases studied, but these cells comprised only the 5% of dermal lymphocytes. Exocytosis of lymphocytes



**Figure 3** CLA + lymphocytes exhibiting exocytosis and located in the dermis ( $\times 100$ )

was observed in 35% of cases. ICAM-1 was expressed by epidermal keratinocytes in 46% of specimens, and was preferentially localized to basal layer keratinocytes. In some cases, there were patches of ICAM-1<sup>+</sup> keratinocytes in the mid-epidermis. ICAM-1<sup>+</sup> keratinocytes were found in the vicinity of LFA-1 $\alpha$ <sup>+</sup> papillary dermal lymphocytes. Epidermal cells expressed HLA-DR in 64% of the samples with staining mainly of Langerhans cells and little expression by keratinocytes. Exocytosis was mainly of CD4<sup>+</sup>, CD8<sup>+</sup> and CLA<sup>+</sup> lymphocytes (Fig. 3), many of which also expressed LFA-1 $\alpha$ . In lesions with vacuolization of the BMZ, there was a predominance of LFA-1 $\alpha$  expression (73%), followed by ICAM-1 (64%), and HLA-DR on Langerhans cells (55%).

## Discussion

Considered a disease of the tropics, erythema dyschromicum perstans has been described in a large series from Salvador,<sup>34</sup> smaller cohorts of patients from Mexico<sup>11,12,35</sup> and Venezuela,<sup>23,36</sup> and in a patient from Argentina<sup>22</sup>, but there are no publications from Colombia. All our patients presented with grayish hyperpigmented lesions; consistent with the report by Ramirez.<sup>34</sup> An erythematous lesion border was present in 24 patients, most of whom had the disease for at least 1 year. In contrast, Tschen *et al.*<sup>2</sup> and Leonforte and Pelaez<sup>22</sup> described the presence of an active margin in patients with EDP of short duration.

Histopathological analysis of lesions showed BMZ vacuolization in 58% of our patients, which is lower than the 85% reported by Vega *et al.*<sup>35</sup> The perivascular distribution of the infiltrate in 86% of our cases contrasts with the typically band-like infiltrate in lichen planus or its variations.<sup>22,37</sup> Some authors consider EDP and lichen planus pigmentosus to be variants of lichen planus,<sup>1,38</sup> but we believe that EDP is a distinct entity. In both lichen planus and EDP, there are melanophages and BMZ vacuolization. Max Joseph-spaces,

although not observed in all cases of lichen planus, are not present in EDP, and confirmed by our series. The immunopathology of EDP and LP are similar and include populations of helper/inducer (CD4<sup>+</sup>) and cytotoxic (CD8<sup>+</sup>) T cells and epidermal keratinocytes that express HLA-DR<sup>+,2,20,23,39,40</sup>. The average number of mononuclear cells was 1510 mm<sup>-2</sup>. While the density of mononuclear cells has been reported in inflammatory diseases such as leprosy (3600 mm<sup>-2</sup> of infiltrate)<sup>41</sup> and leishmaniasis (8000 mm<sup>-2</sup>),<sup>32</sup> to our knowledge, this is the first report on cellular density in EDP.

It has been shown that ICAM-1 (CD54) is undetectable in normal skin, but it is expressed focally in keratinocytes of patients with inflammatory skin diseases. Epidermal ICAM-1 expression was found in 46% of our patients, reinforcing the inflammatory nature of EDP. The location of the LFA-1 $\alpha$  + lymphocytes in the papillary dermis apposed to an ICAM-1 + dermal-epidermal junction, supports a process in which lymphocytes are dependent on adhesion.<sup>44</sup> In 22 patients in which basal vacuolization was evaluated, we found LFA-1 $\alpha$  expression in 73% and 64% had ICAM-1 expression, supporting a role for these two adhesion molecules in the development of BMZ damage in EDP.

## References

- Gadanne BM, Camisa C. Lichenoid dermatitides (lichen planus, keratosis lichenoides and erythema dyschromicum perstans). In: Arndt K, Leboit P, Robinson J, eds. *Cutaneous Medicine and Surgery*, 1st edn. Philadelphia: W.B. Saunders, 1996: 241.
- Tschen JA, Tschen EA, McGavran MH. Erythema dyschromicum perstans. *J Am Acad Dermatol* 1980; 2: 295-302.
- Ramírez CO. Los Cenicientos: Problema clínico. *Memorias del Primer Congreso Centroamericano de Dermatología*. San Salvador, El Salvador, 1957: 122-130.
- Ramírez O, Lopez Lino DG. Estado Actual de la Dermatitis Cenicienta. Sinonimia- Erythema dyschromicum perstans. *Med Cutan Ibero Lat Am* 1984; 12: 11-18.
- Homez-Chacin J, Barroso C. On the etiopathogenic of the erythema dyschromicum perstans: possibility of a melanosis neurocutaneous. *Dermatol Venez* 1996; 4: 149-151.
- Novick NL, Phelps R. Erythema dyschromicum perstans. *Int J Dermatol* 1985; 24: 630-633.
- Person JR, Rogers RS 3rd. Ashy dermatosis: An apoptotic disease? *Arch Dermatol* 1981; 117: 701-704.
- Lee SJ, Chung KY. Erythema dyschromicum perstans in early childhood. *J Dermatol* 1999; 26: 119-121.
- Lambert WC, Schwartz RA, Hamilton GB. Erythema dyschromicum perstans. *Cutis* 1986; 37: 42-44.
- Dominguez L, Soto L. Pigmentary problems in the tropics. *Dermatol Clinics* 1994; 12: 777-783.
- Dominguez Soto L, Vega Memije ME, Arenas R, *et al.* Dermatitis cenicienta. Estudio clínico-patológico de 20 pacientes (1989-90). *Gac Med Mex* 1992; 128: 623-628.

- 12 Navarro Jimenez BR, Sanchez Navarro LM. Dermatitis cenicienta (Erythema dyschromicum perstans). Estudio prospectivo de 23 pacientes. *Med Cutan Ibero Lat Am* 1988; 16: 407-412.
- 13 Penagos H, Jimenez V, Fallas V, et al. Chlorothalonil, a possible cause of erythema dyschromicum perstans (ashy dermatitis). *Contact Dermatitis* 1996; 35: 214-218.
- 14 Zenorola P, Bisceglia M, Lomuto M. Ashy dermatosis associated with cobalt allergy. *Contact Dermatitis* 1994; 31: 53-54.
- 15 Combemale P, Faisant M, Guennoc B, et al. Erythema dyschromicum perstans: report of a new case and critical review of the literature. *J Dermatol* 1998; 25: 747-753.
- 16 Molinero J, Vilata JJ, Nagore E, et al. Ashy dermatosis in an HIV antibody-positive patient. *Acta Derm Venereol* 2000; 80: 78-79.
- 17 Pinkus H. Lichenoid tissue reactions. A speculative review of the clinical spectrum of epidermal basal cell damage with special reference to erythema dyschromicum perstans. *Arch Dermatol* 1973; 107: 840-846.
- 18 Baranda L, Torres-Alvarez B, Cortes-Franco R, et al. Involvement of cell adhesion and activation molecules in the pathogenesis of erythema dyschromicum perstans (ashy dermatitis). The effect of clofazimine therapy. *Arch Dermatol* 1997; 325-329.
- 19 de la Faille-Kuyper EH, de la Faille HB. An immunofluorescence study of lichen planus. *Br J Dermatol* 1974; 90: 365-371.
- 20 Berger RS, Hayes TJ, Dixon SL. Erythema dyschromicum perstans and lichen planus: are they related? *J Am Acad Dermatol* 1989; 21: 438-442.
- 21 Naidorf KF, Cohen SR. Erythema dyschromicum perstans and lichen planus. *Arch Dermatol* 1982; 118: 683-685.
- 22 Leonforte JL, Peláez de di Bari O. Eritema discromico perstans versus liquen plano. *Med Cutan Ibero Lat Am* 1987; 15: 89-92.
- 23 Gross A, Tapia FJ, Mosca W, et al. Mononuclear cell sub-populations and infiltrating lymphocytes in erythema dyschromicum perstans and vitiligo. *Histol Histopathol* 1987; 2: 277-283.
- 24 Toussaint S, Kamino H. Noninfectious erythematous, papular and squamous diseases. In: Elder D, Elenitsas R, Jaworsky C, et al. eds. *Lever's Histopathology of the Skin*, 8th edn. Philadelphia: Lippincott-Raven, 1997: 154-155.
- 25 Perez A, Henríquez A, Gross A, et al. Study in situ of the cellular immunity in erythema dyschromicum perstans and vitiligo. *Dermatol Venez* 1986; 24: 89-95.
- 26 Sanchez NP, Pathak MA, Sato SS, et al. Circumscribed dermal melaninosis: classification, light, histochemical, and electron microscopic studies on three patients with the erythema dyschromicum perstans type. *Int J Dermatol* 1982; 21: 25-31.
- 27 Dustin ML, Springer TA. Lymphocyte function-associated antigen-1 (LFA-1) interaction with intercellular adhesion molecule-1 (ICAM-1) is one of at least three mechanisms for lymphocyte adhesion to cultured endothelial cells. *J Cell Biol* 1988; 107: 321-331.
- 28 Makgoba MW, Sanders ME, Ginther Luce GE, et al. Functional evidence that intercellular adhesion molecule-1 (ICAM-1) is a ligand for LFA-1-dependent adhesion in T cell-mediated cytotoxicity. *Eur J Immunol* 1988; 18: 637-640.
- 29 Dustin ML, Singer KH, Tuck DT, et al. Adhesion of T lymphoblasts to epidermal keratinocytes is regulated by interferon gamma and is mediated by intercellular adhesion molecule-1 (ICAM-1). *J Exp Med* 1988; 167: 1323-1340.
- 30 Stingl G, Katz SI, Shevach EM, et al. Analogous functions of macrophages and Langerhans cells in the initiation in the immune response. *J Invest Dermatol* 1978; 71: 59-64.
- 31 Tapia F, Mosca W, Gross A. Study *in vitro* and *in situ* of the immune response in the erythema dyschromicum perstans and vitiligo. In: Bianco N, Machado I, eds. *Inmunologia Clinica*, 3rd edn. New York: Conicit, 1989: 233-234.
- 32 Isaza D, Restrepo M, Restrepo R, et al. Immunocytochemical and histopathologic characterization of lesions from patients with localized cutaneous leishmaniasis caused by *Leishmania Panamensis*. *Am J Trop Med Hyg* 1996; 55: 365-369.
- 33 Taylor CR. Staining protocols and practical procedures, Appendix 1. In: Taylor CR, Cote RJ, eds. *Immunomicroscopy: a Diagnostic Tool for the Surgical Pathologist*. Philadelphia: W.B. Saunders, 1986: 365.
- 34 Ramirez CO. The ashy dermatosis (erythema dyschromicum perstans): epidemiological study and report of 139 cases. *Cutis* 1957; 3: 244-247.
- 35 Vega ME, Waxtein L, Arenas R, et al. Ashy Dermatitis and lichen planus pigmentosus: a clinicopathological study of 31 cases. *Int J Dermatol* 1992; 31: 90-94.
- 36 Piquero-Martin J, Perez-Alfonzo R, Abrusci V, et al. Clinical trial with clofazimine for treating erythema dyschromicum perstans. Evaluation of cell-mediated immunity. *Int J Dermatol* 1989; 28: 198-200.
- 37 Mosher D, Fitzpatrick T, Ortonne J, et al. Hypomelanosis and hypermelanosis. In: Fitzpatrick T, Freedberg I, Eisen A, eds. *Dermatology in General Medicine*, 5th edn. New York: McGraw-Hill, 1999: 1008.
- 38 Pandya AG, Guevara IL. Disorders of hyperpigmentation. *Dermatol Clin* 2000; 18: 91-98.
- 39 Miyagawa S, Komatsu M, Okuchi T, et al. Erythema dyschromicum perstans. Immunopathologic studies. *J Am Acad Dermatol* 1989; 20: 882-886.
- 40 Kark EC, Litt JZ. Ashy dermatosis: a variant of lichen planus?. *Cutis* 1980; 25: 631-633.
- 41 Modlin RL, Hofman FM, Horwitz DA, et al. In situ identification of cells in human leprosy granulomas with monoclonal antibodies to interleukin-2 and its receptor. *J Immunol* 1984; 132: 3085-3090.
- 42 Abbas AK, Lichtman AH, Pober JS, eds. *Cellular and Molecular Immunology*, 5th edn. Philadelphia: Saunders, 2003: 289-293.
- 43 Tapia FJ, Cáceres-Dittmar G, Acuña L, et al. Epidermal Langerhans cells in infectious diseases. *Histol Histopathol* 1989; 4: 499-508.

- 44 Wawryk SO, Novotny JR, Wicks IP, *et al.* The role of the LFA-1/ICAM-1 interaction in human leukocyte homing and adhesion. *Immunol Rev* 1989; 108: 135-161.
- 45 Barker JN, Mitra RS, Griffiths CE, *et al.* Keratinocytes as initiators of inflammation. *Lancet* 1991; 337: 211-214.
- 46 Heald P, Edelson R. Cutaneous T-cell lymphomas. In: Fitzpatrick T, Freedberg I, Eisen A, *et al.*, eds. *Dermatology in General Medicine*, 5th edn. New York: McGraw-Hill, 1999: 1227.