

Lymphocyte Subset Diversity in Idiopathic CD4⁺ T Lymphocytopenia

P. TASSINARI, L. DEIBIS, N. BIANCO, AND G. ECHEVERRÍA DE PÉREZ*

Instituto de Immunología, Facultad de Medicina, Universidad Central de Venezuela, Caracas, Venezuela

Received 14 August 1995/Returned for modification 4 January 1996/Accepted 3 June 1996

The clinical and public health importance of CD4⁺ T lymphocytopenia without human immunodeficiency virus infection is still unclear. We describe herein two new human immunodeficiency virus-negative patients with low numbers of peripheral CD4⁺ T cells and opportunistic infections (cerebral toxoplasmosis and tuberculosis plus extrapulmonary histoplasmosis). The low numbers of CD4⁺ CD29⁺ memory cells, the high percentage of $\gamma\delta$ T-cell receptor cells, and the recovery of CD4⁺ cells after treatment were remarkable.

Idiopathic CD4⁺ T lymphocytopenia has recently been recognized and defined by the Centers for Disease Control and Prevention to include patients with <300 CD4⁺ cells per mm³ or a CD4⁺ cell count of <20% of total T cells on two occasions, no evidence of human immunodeficiency virus type 1 (HIV-1) or HIV-2 infection, and the absence of any defined immunodeficiency or therapy associated with depressed levels of CD4⁺ T cells (1). The clinical presentation is characterized by opportunistic infections and unexplained immunodeficiency (2, 4-6, 8). This report describes the clinical and laboratory findings for two new patients who presented with opportunistic infections and idiopathic CD4⁺ lymphocytopenia in the absence of risk factors for HIV infection.

Patients were tested for anti-HIV-1 and anti-HIV-2 antibodies by enzyme immunoassay (EIA) and Western blotting (immunoblotting) (Abbott and Organon Teknika). Serological assays for human T-cell lymphotropic virus (HTLV) included EIA (Cambridge Biotech) and immunofluorescence assays prepared with HTLV-1 and HTLV-2 cell lines (MT2 and MoT). Immunologic studies of levels of immunoglobulin G (IgG), IgA, IgD, and kappa and lambda light chains in serum (QM-300 Automated Analyzer; Kallestead Diagnostics) were performed. Tests for antibodies to Epstein-Barr virus and cytomegalovirus were done by radioimmunodiffusion. The presence of viral markers for hepatitis B (hepatitis B surface antigen, anti-hepatitis B surface, and anti-hepatitis B core) was determined by EIA (Hepanostika; Organon Teknika), and the presence of anti-hepatitis C virus was determined by a second-generation EIA (Ortho Diagnostic System). Single- and dual-color flow-cytometric analyses (FCA) (EPICS-753; Coulter Corporation) were performed with monoclonal antibodies (Coulter Immunology Corporation) for CD3, CD4, CD8, CD19, CD56, CD14, CD29, and CD45RA. Lymphocyte proliferation to phytohemagglutinin (5 μ g/ml) and pokeweed mitogen (1:200) was assessed on peripheral blood mononuclear cells as previously reported (9).

Case 1. A 44-year-old Venezuelan heterosexual male presented with a primary seizure in February 1992. Cerebral magnetic resonance imaging (MRI) showed alterations on the right temporal lobe suggestive of space-occupying lesions. A biopsy sample taken from one of the lesions revealed a lymphocytic infiltrate, astrocytic proliferation, necrosis, and the presence of

Toxoplasma gondii cysts. Toxoplasmosis tests resulted in a positive hemagglutination reaction with a titer of 1/16,348 and an intradermal reaction at 48 h of 5 mm. Tests for specific IgM and antibodies to HIV and HTLV were negative. Levels of immunoglobulins in serum were normal. FCA showed CD4⁺ and CD8⁺ T-lymphocyte depression (Table 1). Purified protein derivative and candida skin reactions were 0 and 6 mm, respectively. The patient had a history of hypersensitivity to sulfonamides; therefore, he was initially treated with valproic acid and clindamycin for a month and showed clinical improvement, resolution of central nervous system lesions (detected by MRI), and an increase in CD4⁺ cell values (Fig. 1). The patient was well for 11 months, until May 1993, when he complained of drowsiness and a recent-memory deficit. A new MRI revealed multiple central nervous system lesions. Tests for HIV-1 and -2 and HTLV-1 and -2 were again negative. IgG but not IgM to *T. gondii* was detected (titer of 1/4,096), and a skin test for toxoplasma was negative. Serum immunoglobulin levels remained normal. A follow-up FCA (June 1993) showed normal levels of CD3⁺ cells and low levels of both CD4⁺ and CD8⁺ cells (Table 1). In the evaluation of CD3 versus CD4 and CD8 by dual color FCA, we found a diminution of both CD3⁺ CD4⁺ cells (13%; 128 cells per mm³) and CD3⁺ CD8⁺ cells (10%; 99 cells per mm³). Memory cells (CD29⁺) in peripheral blood mononuclear cells were depleted (12%; 118 cells per mm³), while levels of naive cells (CD45RA⁺) were increased (76%; 750 cells per mm³). When both subpopulations were assessed by dual-color FCA with monoclonal antibodies for CD3, a predominant depletion of memory cells was confirmed (CD3⁺ CD29⁺ cells, 11% [108 cells per mm³], versus CD3⁺ CD45RA⁺ cells, 75% [740 cells per mm³]); however, both subpopulations were depleted as determined by dual-color FCA with monoclonal antibodies for CD4 (CD4⁺ CD29⁺ cells, 3% [30 cells per mm³], and CD4⁺ CD45RA⁺ cells, 5% [49 cells per mm³]) and CD8 (CD8⁺ CD29⁺ cells, 7% [69 cells per mm³], and CD8⁺ CD45RA⁺ cells, 4% [39 cells per mm³]). T-cell receptor expression was found to be inverted when $\alpha\beta$ cells (22%; 217 cells per mm³) were compared with $\gamma\delta$ cells (72%; 710 cells per mm³). At the same date, peripheral blood mononuclear cells showed diminished proliferation (compared with controls) when stimulated with pokeweed mitogen (2,000 versus 148,000 cpm) and phytohemagglutinin (16,000 versus 186,000 cpm). A bone marrow biopsy performed in June 1993 showed no alterations; the distribution of lymphocytes and their subsets was comparable to the peripheral blood values (data not shown). The FCA in January 1994 again showed normal levels of CD3⁺ cells with low levels

* Corresponding author. Mailing address: Institute of Immunology, c/o Aerocav No. 1216, P.O. Box 02-5304, Miami, FL 33102-5304. Phone and fax: (582) 672-0371.

TABLE 1. Results of lymphocyte phenotyping^a

Patient and date ^b	No. of leukocytes/mm ³	Lymphocytes		CD3 ⁺ cells		CD4 ⁺ cells		CD8 ⁺ cells		No. of CD4 ⁺ cells/no. of CD8 ⁺ cells	CD19 ⁺ cells		CD56 ⁺ cells	
		%	No./mm ³	%	No./mm ³	%	No./mm ³	%	No./mm ³		%	No./mm ³	%	No./mm ³
Patient 1														
3/92	7,750	27	2,093	87	1,820	17	356	9	188	1.89	ND ^c	ND	ND	ND
4/92	3,500	48	1,478	88	1,478	33	554	12	201	2.7	ND	ND	ND	ND
5/93	4,700	21	987	96	948	15	148	12	118	1.25	0	0	ND	ND
6/93	4,800	56	2,688	88	2,231	17	457	14	376	1.2	ND	ND	ND	ND
10/93	5,200	64	3,328	97	3,228	22	732	14	466	1.5	ND	ND	ND	ND
1/94	6,100	54	3,294	88	2,899	25	824	14	461	1.7	0	0	2	56
5/94	4,600	61	2,806	89	2,497	18	505	15	421	1.2	0		ND	ND
Patient 2														
4/94	7,500	23	1,725	15	259	2	35	20	345	0.1	ND	ND	ND	ND
5/94	5,200	30	1,560	10	156	3	46	34	530	0.08	20	312	45	702

Normal range 5,850–8,150 20–59 1,740–2,832 55–81 1,093–1,926 35–36 884–1,168 18–40 372–886 0.96–2.4 7–23 162–244 9–13 222–384

^a Results are expressed as the arithmetic mean \pm standard deviation of the absolute count per cubic millimeter and percentages of fluorescent cells by flow cytometry.

^b Month/year.

^c ND, not done.

of CD4⁺ cells, CD8⁺ cells, CD3⁺ CD4⁺ cells (19%; 626 cells per mm³), and CD3⁺ CD8⁺ cells (13%; 428 cells per mm³). Interestingly, levels of CD3⁺ CD56⁺ cells were low, while no CD19⁺ cells were detected (Table 1). The EIAs for HIV antibodies performed with samples from the patient's wife and children were negative. Also, the lymphocyte subpopulations of the wife were normal. The patient was treated with clindamycin, pyrimethamine, folinic acid, and valproic acid, with total remission of the symptoms. The last MRI, performed on May 1994, was normal, and the patient has remained asymptomatic.

Case 2. In December 1993, a 46-year-old Venezuelan woman presented with a 2-cm axillary adenopathy. A biopsy showed histoplasmosis. In February 1994, she developed a

primary seizure and cerebral MRI demonstrated alterations at the left parietal lobe suggestive of space-occupying lesions. A biopsy from the lesion revealed tuberculoma; a chest radiograph was normal. Serum immunoglobulin levels were normal. Tests for antibodies to HIV-1 and -2 and HTLV-1 and -2 were negative. The only alterations observed in the FCA were CD3⁺ and CD4⁺ lymphocytopenia (Table 1). Skin tests for purified protein derivative, candida, and histoplasma were negative. In May 1994, the patient presented with drowsiness, and a cerebral tomography revealed a 6-mm lesion of the right front temporal region with a dense perilesional area. A bone marrow biopsy showed no histological alterations, and cultures for fungus and mycobacteria were negative. Results of an abdominal echogram, a mammogram, chest x rays, and a digestive-tract

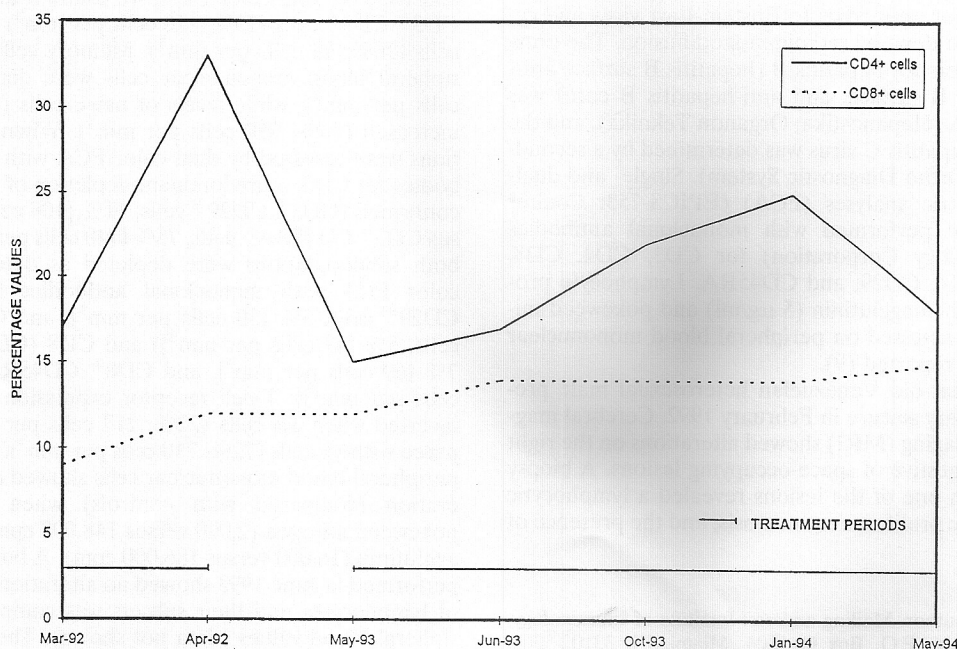


FIG. 1. Variations in levels of CD4⁺ and CD8⁺ T cells over time for patient 1.

endoscopy were within normal limits. A new FCA showed persistent CD3⁺ and CD4⁺ lymphocytopenia, absolute depletion of memory cells (CD29⁺ cells, 0%), and low levels of naive cells (CD45RA⁺ cells, 28%; 337 cells per mm³). In addition, there was an increase in numbers of CD19⁺ cells (20%; 312 cells per mm³) and CD56⁺ cells (45%; 702 cells per mm³). Treatment with isoniazid, streptomycin, rifampin, and itraconazole was started, and clinical improvement followed. However, by July 1994, the patient was anorexic and had lost 10 kg in the previous month. A new cerebral tomography revealed hydrocephaly and persistence of the lesions previously described. She developed acute tubulointerstitial nephropathy, probably due to miliary tuberculosis, and hepatitis, probably secondary to itraconazole treatment, and died in August 1994.

Preliminary epidemiological studies of patients with idiopathic CD4⁺ T lymphocytopenia and unexplained opportunistic infections suggest that the causes of this syndrome are heterogeneous (8), representing various clinical and immunologic states (2, 5). The alterations in the subpopulations of T lymphocytes observed in these patients are different from those seen in patients with HIV infection (3, 9), since there is no increase in numbers of CD8⁺ lymphocytes and thus there is a tendency to general lymphopenia at the onset of the symptoms; there could also be a decrease in other cellular populations such as B lymphocytes and natural killer cells, and there is not a progressive decrease in numbers of CD4⁺ lymphocytes. Our two patients had different clinical and immunologic characteristics, although they both met the criteria for idiopathic CD4⁺ T lymphocytopenia syndrome, confirming that this is a very heterogeneous entity. Patient 1 presented with normal levels of CD3⁺ cells and low levels of CD4⁺, CD8⁺, CD19⁺, and CD56⁺ cells. There were high percentages of $\gamma\delta$ T-cell receptor, CD3⁺, CD4⁻, and CD8⁻ cells, in contrast with the 1 to 5% usually present in controls. The physiologic significance of $\gamma\delta$ T cells remains elusive, but they have recently been described in association with a number of bacterial and parasitic infections (7).

The initiation of specific treatment for toxoplasmosis was associated with an increase in numbers of CD4⁺ lymphocytes, while the suspension of such treatment was followed by a new decrease in numbers of CD4⁺ lymphocytes (Fig. 1). The evaluation of memory and naive cells from the first patient demonstrated a diminution of memory cells in both peripheral blood mononuclear cells and CD3⁺ lymphocytes and a deple-

tion of both subpopulations in CD4⁺ lymphocytes. The findings differ from the data reported by Vertes et al. (10), who found a shift from naive T-helper cells toward memory T-helper cells in one patient with idiopathic CD4⁺ T lymphocytopenia and selective IgA deficiency.

On the other hand, patient 2 had low levels of CD3⁺ and CD4⁺ lymphocytes, with normal levels of CD8⁺ cells; among these, CD3⁻ CD8⁺ cells were detected. This population may represent lymphocytes expressing CD8 and CD56 in the absence of CD3 (a dual-color FCA for CD8 and CD56 was not done). Thus, a striking diversity in lymphocyte subsets may be one of the hallmarks of this syndrome. The recovery of CD4⁺ cells after treatment further distinguishes its possible etio-pathogenesis from that of HIV infection.

This work was funded by Programa Genic (CONICIT-CNRIC).

REFERENCES

1. Centers for Disease Control. Unexplained CD4⁺ T-lymphocyte depletion in persons without evident HIV infection—United States. 1992. *Morbidity and Mortality Weekly Report*. 41:541-545.
2. Duncan, R., C. Fordham von Reyn, G. Alliegro, Z. Toossi, A. Sugar, and S. Levitz. 1993. Idiopathic CD4⁺ T-lymphocytopenia: four patients with opportunistic infections and no evidence of HIV infection. *N. Engl. J. Med.* 328:393-398.
3. Fauci, A. 1991. Immunopathogenic mechanisms in human immunodeficiency virus (HIV) infection. *Ann. Intern. Med.* 114:678-693.
4. Gupta, S., C. Ribak, S. Gollopudi, C. Kim, and S. Salahuddin. 1992. Detection of a human intracisternal retroviral particle associated with CD4⁺ T-cell deficiency. *Proc. Natl. Acad. Sci. USA* 89:7831-7835.
5. Ho, D., Y. Cao, T. Zhu, C. Farthing, N. Wang, G. Gu, R. Schooley, and E. Daar. 1993. Idiopathic CD4⁺ T-lymphocytopenia—immunodeficiency without evidence of HIV infection. *N. Engl. J. Med.* 328:380-385.
6. Laurence, J., F. Siegal, E. Schattner, I. Gelman, and S. Morse. 1992. Acquired immunodeficiency without evidence of infection with human immunodeficiency virus type 1 and 2. *Lancet* 340:273-274.
7. Pechhold, K., D. Wesch, S. Schondelmaier, and D. Kabelitz. 1994. Primary activation of V γ 9-expressing $\gamma\delta$ T cells by *Mycobacterium tuberculosis*. *J. Immunol.* 152:4984-4989.
8. Smith, D., J. J. Neal, and S. D. Holmberg. 1993. Unexplained opportunistic infection and CD4⁺ T-lymphocytopenia without HIV infection. *N. Engl. J. Med.* 328:373-379.
9. Tassinari, P., L. Deibis, I. Blanca, N. E. Bianco, and G. Echeverría de Pérez. 1995. Decreased T-cell proliferative response to common environmental antigens could be an indicator of early human immunodeficiency virus-mediated lymphocyte lesions. *Clin. Diagn. Lab. Immunol.* 2:404-407.
10. Vertes, D., M. Linden, and J. Carey. 1995. Idiopathic CD4⁺ T-lymphocytopenia: analysis of a patient with selective IgA deficiency and no evidence of HIV infection. *Cytometry* 22:40-44.